and the proximal part of left SFA. Atherectomy was performed with SilverHawk Plaque Excision System (Ev3 Inc. Nathan Lane North Plymouth, MN) on the right SFA. After this procedure two monorail self expandible stents (7 mmx10 cm) were implanted on the SFA artery respectively. Then two monorail self expandible stent (7 mmx10 cm) was implanted on the SFA artery respectively.

RESULTS: Distal pulses were palpable in the intensive care unit controls. The patient was discharged in the 5th postoperative day with palpable distal pedal pulses, with resting ABI 1.1 on the left and 1.0 on the right and completely healed diabetic ulcer. Walking distance have increased and also the stents in the bilateral SFA arteries were patent in the color Doppler ultrasonography in first and third month control examinations.

CONCLUSIONS: Endovascular interventions should be thought as a treatment alternative for critical limb ischemia with the advantages of decreasing the primary major amputation rates and increasing the extremity rescue rates and survival rate, due to the fact that they decrease the hospital staying time. In the total occluded lesions, atherectomy is reliable method which have acceptable primary and secondary partency rates and it is minimal invasive method to be used in critical limb ischemia.

PP-382 DEVELOPMENT OF COMPARTMENT SYNDROME AFTER GUNSHOT INJURY DUE TO RADIAL ARTERY TRANSECTION

M. Tavlasoglu[1], Z. Arslan[3], A. Guler[2], A. Amrahov[2], M. Kurkluoglu[2], A.B. Durukan[4], M.A. Sahin[2], F.G. Yesil[2]
[1]Department of Cardiovascular Surgery, Diyarbakir Military Medical Hospital, Diyarbakir, Turkey
[2]Department of Cardiovascular Surgery, Gulhane Military Medical Academy, Ankara, Turkey
[3]Department of Cardiology, Gulhane Military Medical Academy, Ankara, Turkey
[4]Department of Cardiovascular Surgery, Medicana International Ankara Hospital, Ankara, Turkey

OBJECTIVE: The ulnar and the radial arteries are the two main blood vessels of the forearm. Brachial artery continues down the ventral surface of the arm until it reaches the cubital fossa at the elbow. It then divides into the radial and ulnar arteries which run down the forearm. In this article we present development of compartment syndrome after gunshot injury due to radial artery transection although ulnar arterial flow is maintained.

METHODS:45 year-old male patient due to gunshot injury of the left radial artery, 7 cm distal to the brachial artery bifurcation were delivered to our clinic. The ulnar and the radial artery pulses could not be felt and the saturation rates of right hand fingers were smaller than the %70. However the ulnar artery is intact and the arterial flow was determined preserved in Doppler examination in which there was monophasic arterial flow. There was a bullet entrance in ventral face of forearm. The patient was taken to the operation to explore arterial structures. The skin incision was made parallel to radial artery course. Before reaching the neurovascular sheet, excessive hematoma, extending from entrance point of bullet to the brachial artery bifurcation and also from entrance point to the distally, was determined beneath the flexor carpi radialis muscles. The hematoma was drained. The pulse of the ulnar artery was restored. After that the proximal and distal site of radial artery was dissected. Then vascular clamp were applied and the both ends of radial artery were fixed and radial artery was sutured in an end to end fashion.

RESULTS: Subsequently, the pulse of radial artery was restored and able to be felt manually within a few minutes. The fasciotomy was performed and the skin incision was closed with usual manner. The saturation rates of right hand fingers were restored.

CONCLUSIONS: As a result, excessive hematoma causes pressure increase which blocks the arterial flow even if the arterial structure is intact in compartment. In such cases, fasciotomy must be performed and hematoma must be drained regardless of the arterial flow is.

Figure

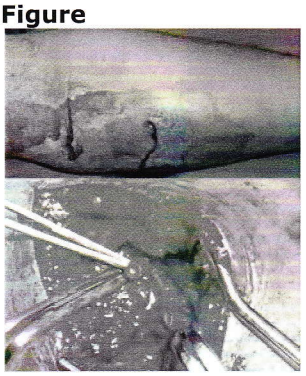

PP-383 REDUCING TENSION IN ANASTOMOSIS SITE WITH A SIMPLE SUSPENSION SUTURE IN BRACHIAL ARTERY IN WHICH SAPHEIN VEIN INTERPOSITION WAS PERFORMED

M.Tavlasoglu[1], A. Guler[2], A. Amrahov[2], M. Kurkluoglu[2], Z. Arslan[3], M.A. Sahin[2], A.B. Durukan[4], F.G. Yesil[2]
[1]Department of Cardiovascular Surgery, Diyarbakir Military Medical Hospital, Diyarbakir, Turkey
[2]Department of Cardiovascular Surgery, Gulhane Military Medical Academy, Ankara, Turkey
[3]Department of Cardiology, Gulhane Military Medical Academy, Ankara, Turkey
[4]Department of Cardiovascular Surgery, Medicana International Ankara Hospital, Ankara, Turkey

OBJECTIVE: The brachial artery is the major blood vessel of the arm. It is the continuation of the axillary artery beyond the lower margin of teres major muscle. It continues down the ventral surface of the arm until it reaches the cubital fossa at the elbow. It then divides into the radial and ulnar arteries which run down the forearm. In some individuals, the bifurcation occurs much earlier and the ulnar and radial arteries extend through the arm. In this article we present Reducing tension in anastomosis site with a simple suspension suture in brachial artery in which saphein vein interposition was performed.

METHODS:35 year-old male patient due to gunshot injury of the left brachial artery just distal to the axillary artery were delivered to our clinic. The ulnar

and the radial artery pulses could not be felt and the saturation rates of right hand fingers were smaller than the %70. There was a bullet entrance in ventral face of arm. The patient was taken to the operation. The skin incision was made parallel to brachial artery course. Before reaching the neurovascular sheet, excessive bleeding was noticed from brachial artery. The bleeding was controlled with finger pressure. While the brachial artery was being pressurized, the proximal and distal site of brachial artery was dissected. Then vascular clamp were applied. The right saphein vein was explored just proximal to the knee. However the calibration of the saphein vein was not enough to be harvested. Therefore right saphenofemoral junction was explored and only 3 cm long saphein vein had enough calibration. So, 3 cm long graft was harvested. Afterwards it was interposed to the brachial artery. The length of graft was about 0.5 cm shorter. Herein, there was tension on both anastomose site and ulnar and the radial artery pulses could not be felt manually, nevertheless the saturation rate was more than 94%. In this fact, a simple 7/0 prolene suspension suture was applied both proximally and distally to the anastomoses site.

RESULTS: The pulses of ulnar and radial arteries could be felt manually within a few minutes.

CONCLUSIONS: As a result, tension on anastomosis site can be reduced with a simple suspension suture by applying both end of artery just proximal and distal to the saphein vein graft.

Figure

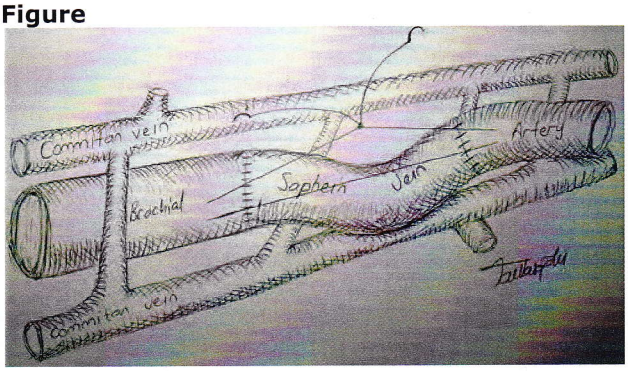

PP-384 A CASE REPORT PRESENTING WITH SYMPTOMS OF ULNAR NERVE COMPRESSION DUE TO ULNAR ARTERY PSEUDOANEURYSM AT GUYON'S CANAL

K. Karabacak[1], G. Genc[2]
[1]Department of Cardiovascular Surgery, Maresal Cakmak Military Hospital, Erzurum, Turkey
[2]Department of Neurology, Maresal Cakmak Military Hospital, Erzurum, Turkey

OBJECTIVE: The ulnar nerve is commonly compressed in the cubital tunnel. The ulnar nerve entrapment at Guyon's canal is rarely seen. We report a case with ulnar neuropathy at Guyon's canal due to compression of the ulnar artery pseudoaneurysm on whom we operated and provided complete clinical and electrophysiological improvement.

METHODS: Case Report

RESULTS:A 20-year-old male patient was admitted to our hospital with the complaints of numbness in the 4th and 5th fingers, hand weakness and puffiness in hand for 2 months. It was learned from his medical history that he falled down wrist-extension position 4 moths ago. In his physical examination, 3x3 cm pulsatile mass in the hypothenar area of the left hand, motor deficit in abduction of the left hand fingers (2/5) and hypoesthesia in sensory area of the ulnar nerve was detected. Nerve conduction studies showed the left ulnar nerve entrapment at Guyon's canal. Doppler Ultrasound revealed the 4x2,5 cm pseudoaneurysm in the Guyon's canal part of the ulnar artery. The operation under the axillary anesthesia was planned. The exploration at Guyon's canal revealed the compression of the ulnar artery pseudoaneurysm to the ulnar nerve. After the dissection of the ulnar nerve from artery, the aneurysmatic part was transected from distal and proximal endings, and the artery was anastomosed end to end.

After the confirmation of patent arterial flow by milking test, the patient was planned to be followed. In the 3 months visit after surgery, it was observed that the arterial anastomosis was open, motor and sensory deficits were completely lost, and there was no compression findings in the nerve conduction studies.

CONCLUSIONS: Arterial injuries are unavoidable facts in hand traumas which hand surgeons frequently encounter. It should be kept in mind that especially in closed injuries, in the patients with subacute or chronic nerve entrapment findings, these clinical findings may arise from the arterial pseudoaneurysms which are running close to the nerves. In explorations during this period, imaging of the arterial structures before the surgery will decrease the possibility of encountering unexpected surprise during surgery.

PP-385 BILETERAL FEMORO-POPLITEAL ARTERY ANEURYSMS

A. Fedakar[1], M.B. Rabus[1], B. Orazgeldiyev[1], H.Erdem[1], C. Koksal[1], M. Ugurlucan[2], M. Balkanay[1]
[1]Kartal Kosuyolu Heart and Research Hospital; Cardiovascular Surgery Clinic, Istanbul, Turkey
[2]Anadolu Medical Center, Istanbul, Turkey

OBJECTIVE: Bileteral femoro-popliteal artery aneurysms are one of the very rare syndromes among cardiovascular disorders. Pathology should be treated immediately when diagnosed otherwise finger loss may ensue due to distal embolisms.

METHODS:A 28-year-old male patient presented to the clinic with a bulging mass in his pemoro-popliteal area. The lesion has long been present and cause to cladicatio intemittans bilaterally. He did not indicate a history of trauma to the region. Physical examination revealed a 5x8 cm in diameter, compressible, pulsatile mass at left knee and 4x7 cm right knee. Bileteral Femoro-popliteal artery aneurysms were detected with doppler ultrasonography. Computerize tomographic angiography of the legs showed that the aneurysms were confined to the Femoro-popliteal artery.