PP-017 Use of ultrasound accelerated thrombolysis in treatment of a patient with intracoronary thrombus and diffuse coronary ectasia: a unique case

Anar Emrah[1], Ugur Cetingok[4], Arzu Murselova[2], Eldar Veliyev[1], Valeh Mammadov[1], Nazim Salimov[2], Elman Samedov[3], Teymur Qasimov[3], Nurlana Osmanova[2], Firdovsi Huseyinov[1], Samed Samedli[2], Samir Abbasov[2]

[1]Department of Cardiovascular Surgery, Central Military Hospital, Baku, Azerbaijan
[2]Department of Cardiology, Central Military Hospital, Baku, Azerbaijan
[3]Department of Anesthesiology, Central Military Hospital, Baku, Azerbaijan
[4]Department of Cardiovascular Surgery, Kudret International Hospital, Ankara, Turkiye

OBJECTIVES

Diffuse coronary ectasia (DCE) is defined as a ≥1.5 fold increase in vessel diameter with polycyclic margins involving more than 2 coronary segments. Nonatherosclerotic coronary ectasia are rare, and the majority of them are diffuse. We presented a case of symptomatic diffuse ectasia of three coronary segments without obstructive coronary artery disease.

CASE

A 41 years old man was admitted with severe chest pain lasting for more than 1 hour. The electrocardiogram was notable for 1.5 mm ST elevation in leads II, III and aVF and 12 mm ST elevation in leads V1-V6. Coronary angiography revealed severe DCE involving all of coronary arteries, total thrombotic occlusion of left anterior descending artery (LAD) and partial thrombotic occlusion of proximal segment of left circumflex artery (LCX). LAD had a diameter of 9 mm and LCX of 8 mm. Right coronary artery (RCA) was open and its diameter was 9 mm, without any notable obstruction. EF was 22%. The patient had no history of Kawasaki disease or other connective tissue disorders.

Primary PTCA, the double balloon PTCA and aspiration thrombectomy were performed unsuccessfully. Despite systemic fibrinolytic therap consisting in continous infusion of r-tPA, his chest pain, cardiac enzymes elevation and cardiogenic shock persisted. A coronary angiogram performed in 24 hours revealed no recanalisation of Involved coronary arteries. It was decided to perform ultrasound accelerated thrombolysis with EKOS system.

EKOS catheter (12 cm) was placed in the LAD via the right femoral artery. r-tPA continuous infusion was administered at a rate of 1mg/h for 18 hours. A following coronariogram revealed total recanalisation of LAD.

Preoperative coronary angiogram



Coronary Angiogram shows totaly thrombosis of ectazic left anterior descending artery and circumflex artery

Placed the EKOS catheter in the LAD



The EKOS catheter (12 cm) was placed in the LAD

Recanalized LAD after the treatment for 18 hours with EKOS system

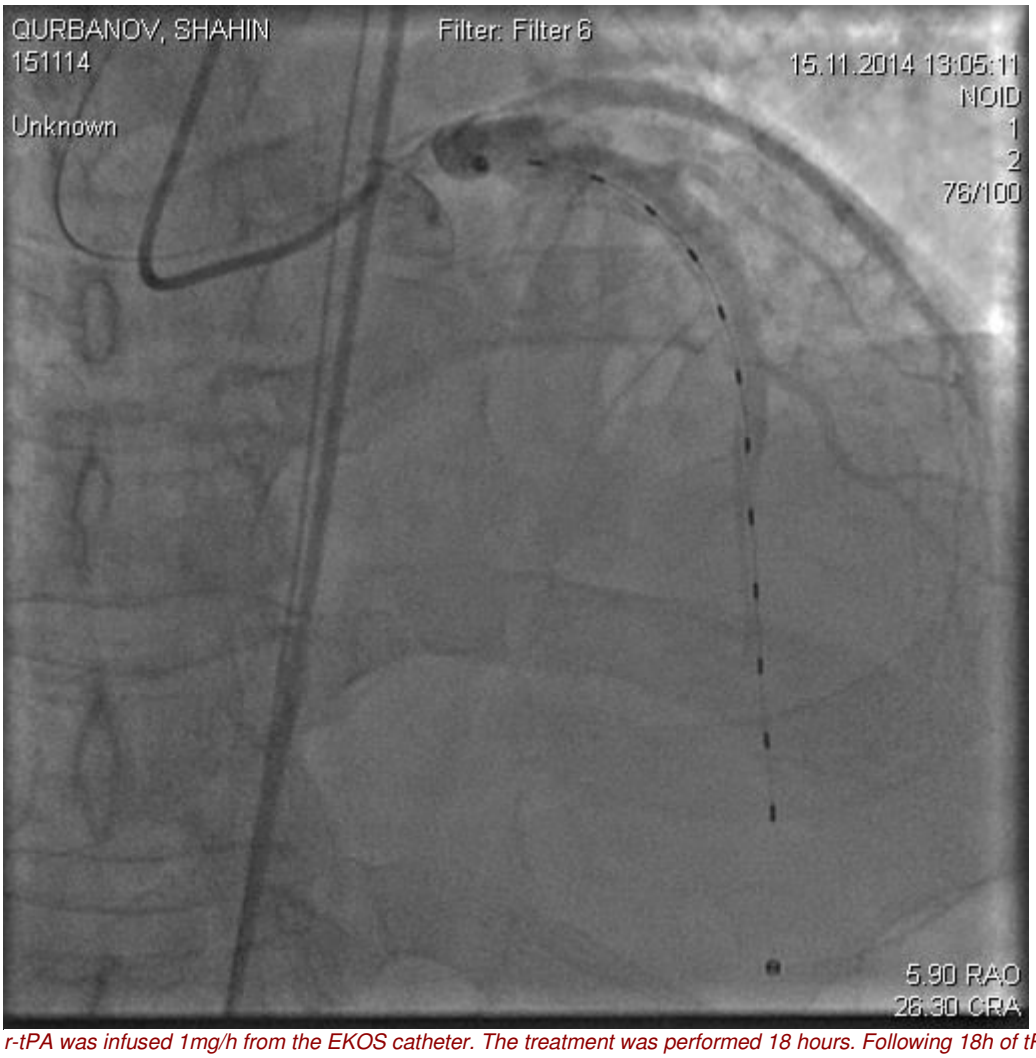

r-tPA was infused 1mg/h from the EKOS catheter. The treatment was performed 18 hours. Following 18h of tPA infusion, LAD was canalized 100%.

Recanalized LAD after the treatment for 18 hours with EKOS system

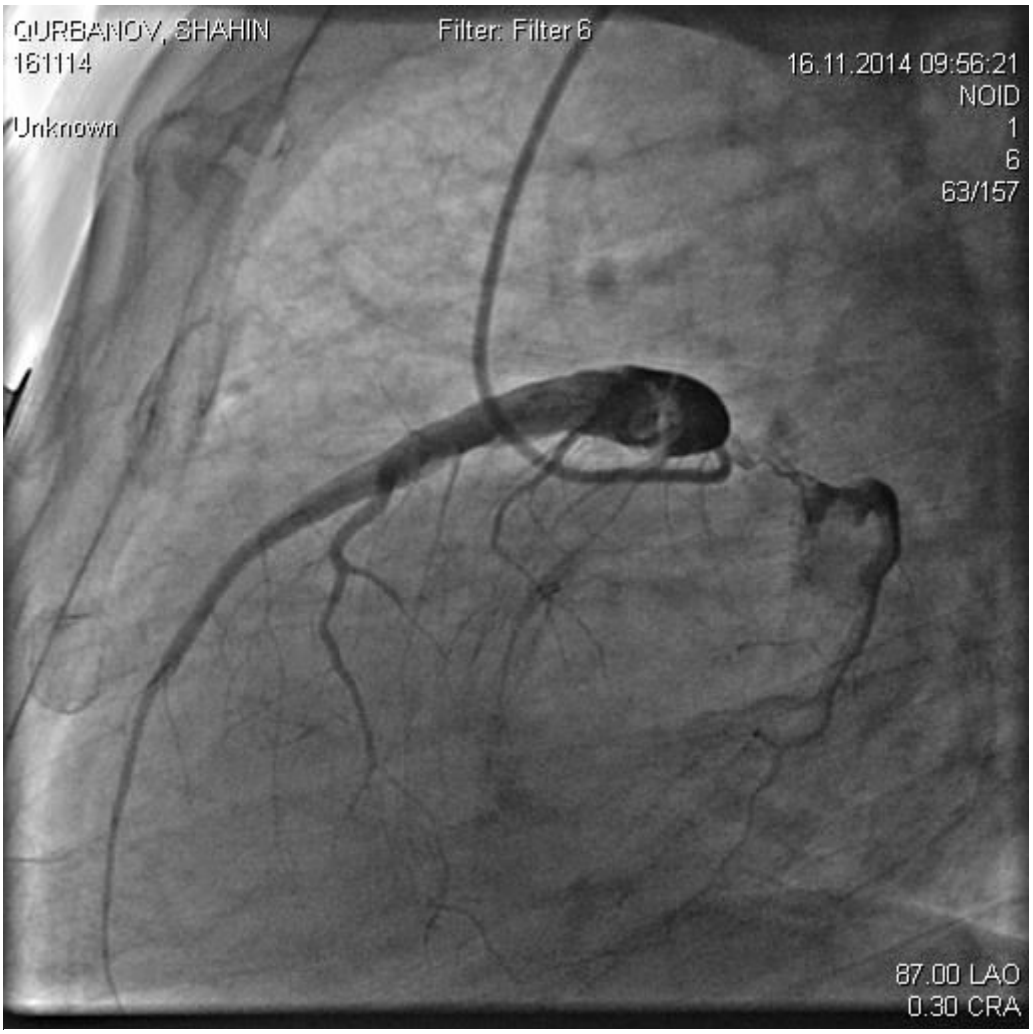

CONCLUSIONS

The treatment strategies that have been used to treat thrombus in native coronary arteries and vein grafts have included chemical agents (thrombolytic, anticoagulant, and antiplatelet agents), ultrasound frequency, and mechanical devices (transmural extraction atherectomy, rheolytic thrombectomy). The thrombolysis is the first choice in the treatment of intracoronary thrombus. Hemorrhagic complications increases proportionally with the dose of thrombolytic agent. Ultrasound accelerated selective thrombolysis is a helpful tool to achieve total recanalisation when the other modalities have failed, especially in ectasic vessels where the coronary blood flow is not impeded by the catheter itself. It may be superior in terms of fast thrombolysis and less systemic hemorrhagic complications compared to systemic thrombolysis, which can be a subject of further studies.

PP-249 The first two hundred cases of open heart surgery in Baku Central Military Hospital

Anar Emrah[1], Arzu Murselova[2], Valeh Mammadov[1], Nazim Salimov[2], Elman Samedov[3], Teymur Qasimov[3], Firdovsi Huseyinov[1], Samed Samedli[2], Samir Abbasov[2], Afet Vekilova[2], Nurlana Osmanova[2], Eldar Veliyev[1]

[1]Department of Cardiovascular Surgery, Central Military Hospital, Baku, Azerbaijan
[2]Department of Cardiology, Central Military Hospital, Baku, Azerbaijan
[3]Department of Anesthesiology, Central Military Hospital, Baku, Azerbaijan

OBJECTIVES

We are reporting the first results of open heart surgery operations in our newly established cardiovascular center belonging to Baku Central Military Hospital.

MATERIALS-METHODS

We evaluated retrospectively results of the first two hundred open heart surgery operations in our center. Our heart team of 30 professionists, including anaesthesist, cardiolog, assisting surgeon, perfussionist and nurses were trained in Ankara Gulhane Military Medical Academy for over 2 years. The first surgeon had a training period of 6 years.

RESULTS

200 patients underwent open heart surgery between 08.10.2013 and 23.12.2014 (175 men, 87.5 %). Mean age was 52 years (11 months-80 years). According to EuroSCORE, 59 patients were found to be in low risk group (0-2 point). 107 patients were found in medium risk group (3-5 point) and 34 patients were in high risk group. Coronary artery bypass grafting was performed in 173 patients (18 OPCAB). The other procedures included one MVR, three AVR, five CABG+AVR, one CABG+mitral valve repair, one CABG+LA ablation, one CABG+LV thrombectomy, one Bentall procedure, one ascending aorta wrapping, one PDA ligation, two LA mixoma excision and 10 secundum type ASD repair, one of which with minimal invasive technique.

Mean intensive care unit stay was 2.2 days and mean duration of hospital stay was 8.6 days. Mortality rate was 0%. Re-exploration was required in 5 patients for hemorrhage. Two patient had postoperative gastrointestinal bleeding. There was no mediastinitis or neurologic complication.

Description of the operations

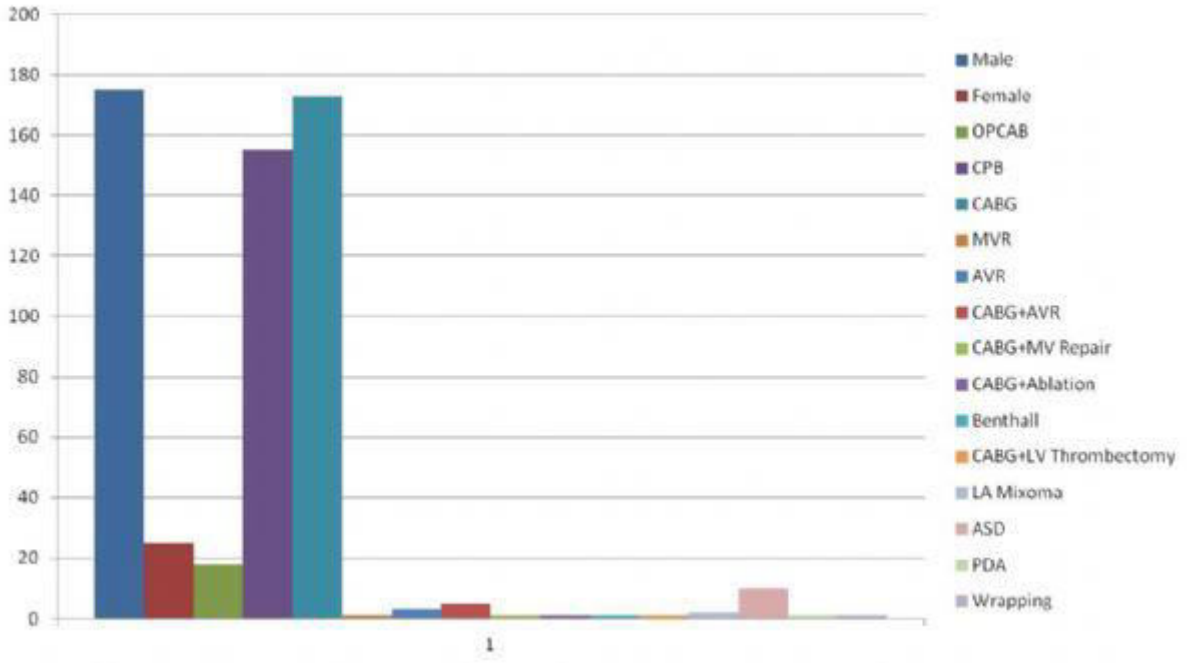

CONCLUSIONS

Establishing a new cardiovascular center is challenging and requires expertise. However, it is possible to get excellent results with a hardworking and enthusiastic team, trained for a mid-long term period in an experienced center.