preparation for hemodynamic stabilization and delayed surgery is important in terms of mortality and morbidity.

PP-261 DETACHMENT AND DISLOCATION OF THERMOREACTIVE CLIPS FROM STERNUM IN LATE POSTOPERATIVE PERIOD DUE TO MISUSE

M. Tavlasoglu[1], M. Kurkluoglu[2], Z. Arslan[3], A. B. Durukan[4], A. Amrahov[2], A. Guler[2], M.A. Sahin[2]
[1]Department of Cardiovascular Surgery, Diyarbakir Military Medical Hospital, Diyarbakir, Turkey
[2]Department of Cardiovascular Surgery, Gulhane Military Medical Academy, Ankara, Turkey
[3]Department of Cardiology, Gulhane Military Medical Academy, Ankara, Turkey
[4]Department of Cardiovascular Surgery, Medicana International Ankara Hospital, Ankara, Turkey

OBJECTIVE: Median sternomy is the most common method of access to the heart and great vessels in cardiac surgical procedures. However, particularly in obese and diabetic patients, some complications may be encountered; such as dehiscence, osteomyelitis, mediastinitis, and superficial wound infection or fistula formation. In order to overcome these complications, some alternative surgical techniques and surgical equipment were designed for sternal closure. 'Nitinol thermo reactive clips' is one of them. In this manuscript, we reported a patient with detachment of thermo reactive clips from sternum in the late postoperative period due to wrong measurement of distance between intercostal spaces.
METHODS:A 44-year-old diabetic man, who underwent 3 reoperations for sternal dehiscence after undergoing Coronary Artery Bypass Graft (CABG) surgery, presented to our department with sternal dehiscence, wound infection and serous discharge from upper half of the incision. During respiration, there was air inflow and outflow, from the anterior mediastinum, through the sternal bone defect which was 1.5x1 cm in size.
After the patient was admitted, chest X-ray in A/P orientation revealed the one of the four nitinol clips that were used during the last revision was dislocated and the next 3 ones was superposed at the level of the xiphoid process. The first clip was and the others were detached from sternum. In lateral view of the chest x-ray, the three superposed nitinol clips were clearly identified at the level of xiphoid process. The patient's medical treatment was adjusted, and tissue cultures were found to be clean for 3 times. After then, the patient was recommended 4th sternal revision. During the operation, first clip was found dislocated to the intercostal space, and the next three nitinol clips, to the sterno-xiphoid level. We found, all of them were oversized. In this stuation we used the Robicsek Modification to expand the distance between intercostal spaces, then we used those oversized clips, which suited the sternum firmly.
RESULTS: Postoperatively, no problems occurred and sternal stability was excellent. The patient was discarged from our clinic at 5th postoperative day with excellent sternal stability.
CONCLUSIONS: As a result, in order to get excellent results while using Nitinol clips in sternal dehiscence repair, we advise our colleagues to use Backaus forceps rather than caliper in measuring distance between intercostal spaces. Because we think that measuring distance with caliper may cause oversizing in learning curve.

Figure

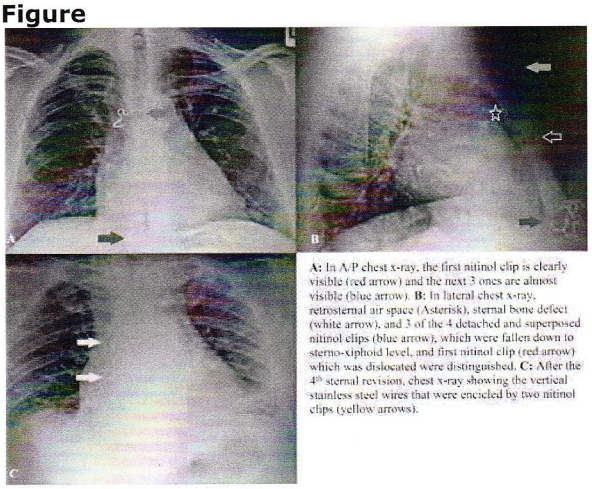

A: In A/P chest x-ray, the first nitinol clip is clearly visible (red arrow) and the next 3 ones are almost visible (blue arrow). B: In lateral chest x-ray, retrosternal air space (Asterisk), sternal bone defect (white arrow), and 3 of the 4 detached and superposed nitinol clips (blue arrow), which were fallen down to sterno-xiphoid level, and first nitinol clip (red arrow) which was dislocated were distinguished. C: After the 4th sternal revision, chest x-ray showing the vertical stainless steel wires that were encircled by two nitinol clips (yellow arrows).

PP-262 FEATURES OF OPERATIVE AND EARLY POSTOPERATIVE PERIOD IN PATIENTS WITH INTRAMURAL COURSE OF CORONARY ARTERIES WITH ATHEROSCLEROTIC LESIONS

O.Gogayeva, G. Knyshov, A Rudenko, L. Dzakhoieva, S.Rudenko, O. Kupchinskij
Department of Surgical Treatment of IHD, National Amosov's Institute of Cardiovascular Surgery AMS of Ukraine, Kyiv, Ukraine

OBJECTIVE: To study the features of operative and early postoperative period of patients with intramural course (IC) of coronary arteries (CA) with atherosclerotic lesions.
METHODS: We analyzed features of perioperative period for 204 patients (182 men, 22 women in middle age of 58.5) with IC of CA, which were found during coronary artery bypass grafting (CABG). Almost all patients had angina pectoris (98.5%), 108 (52.9%) patients had shortness of breath, 143 (70.1%) patients had myocardial infarction in anamnesis. All patients underwent standard diagnostic methods (ECG, ECHO and angiography), CABG was also performed for everybody.
RESULTS: We noticed IC of CA in 9% of the operated patients with ischemic heart disease (IHD). In 181 (88.7%) patients CABG performed off-pump, in 23 (11.3%)-on-pump. Probable operating mortality on a EUROSCORE scale was - 5.4%, while real mortality - 0%. In 175 (85.8%) cases IC had 1 CA, in 25 patients (12.2%) IC had 2 CA and in 4 (2%) cases IC - 3 CA. It should be noted that 13 patients (6.4%) were taken for CABG because of stent restenosis in intramural located CA. In 98 cases (48.3%) IC had LAD. Perioperative period characterized by development of atrial fibrillation (AF) in 27%, ventricular fibrillation (VF) in 7%. During manipulation on IC CA we noticed appearence of ischemic changes on ECG, destabilization of hemodynamics with hypotension.
CONCLUSIONS: The perioperative period in patients with IC and atherosclerotic lesions of CA characterized by frequent disturbances of heart